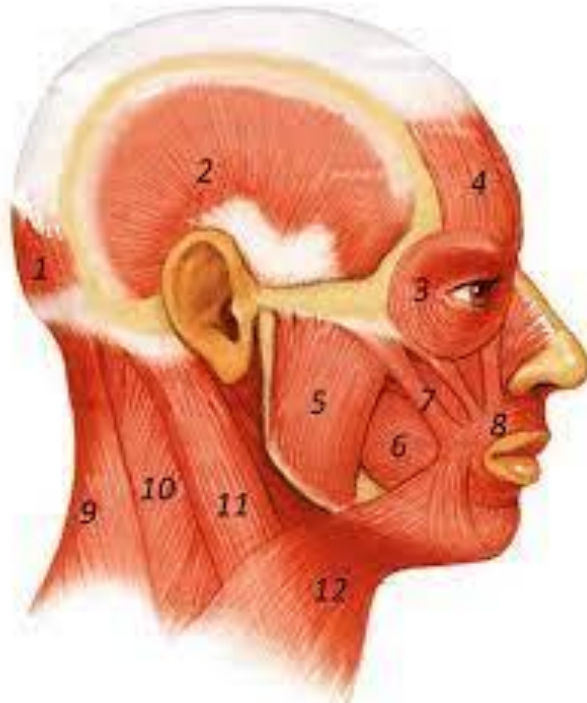

Muscles Of Head & Neck



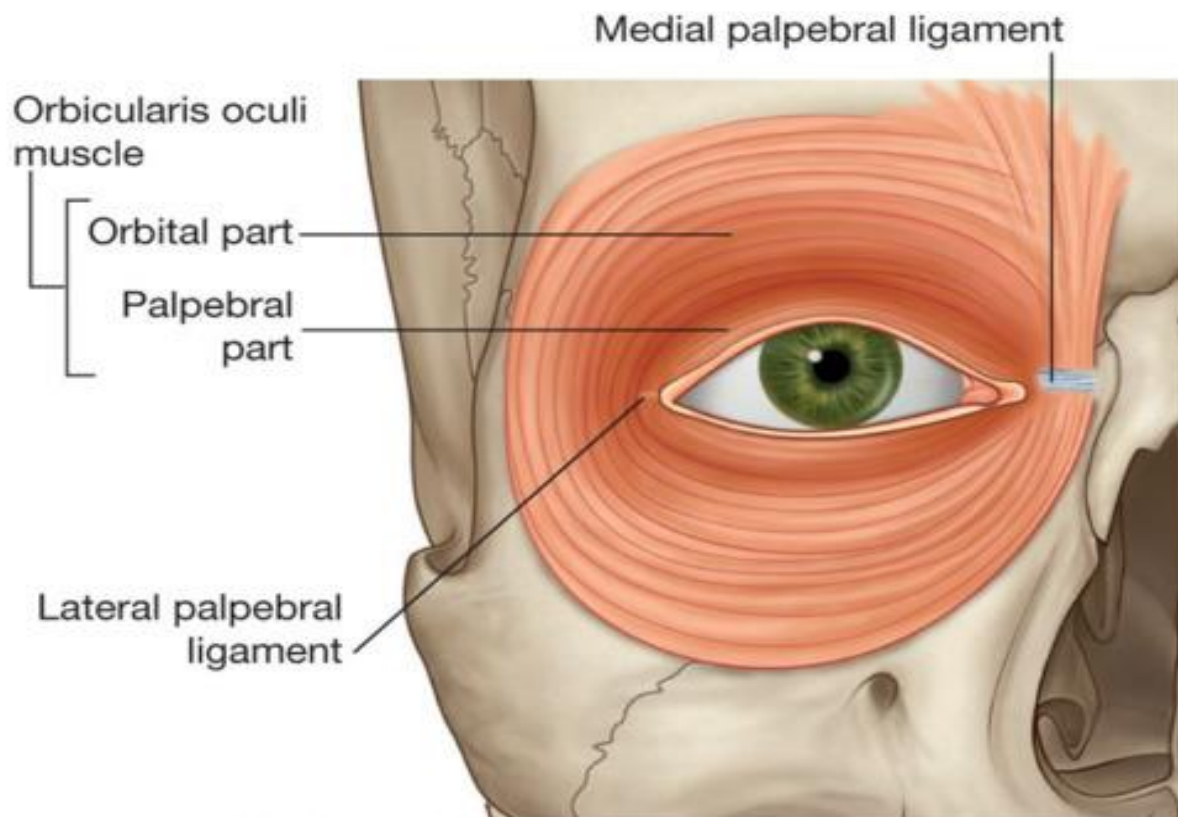
Dr. Wessam Hamed

Ph D & Associate professor of Anatomy & Embryology

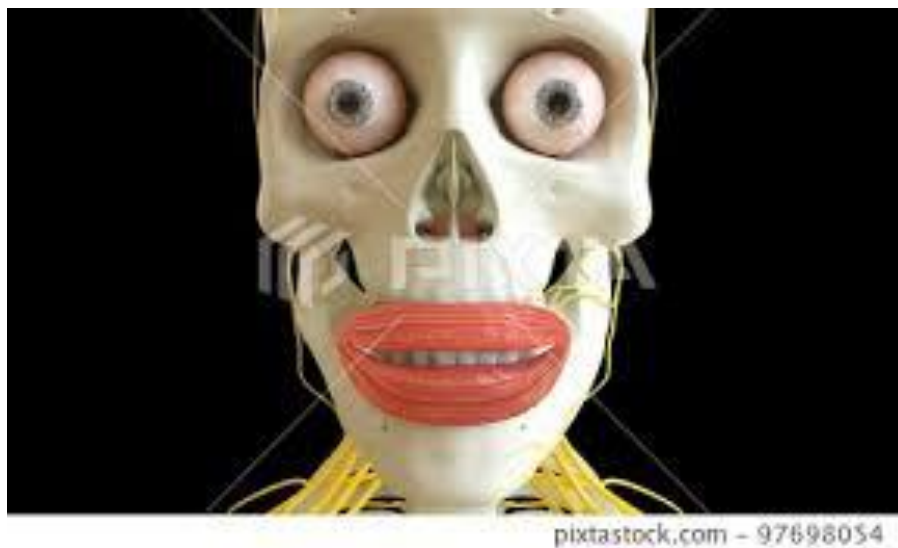Faculty of dentistry Zarqa university of Jordan

Faculty of medicine Mansoura university Egypt

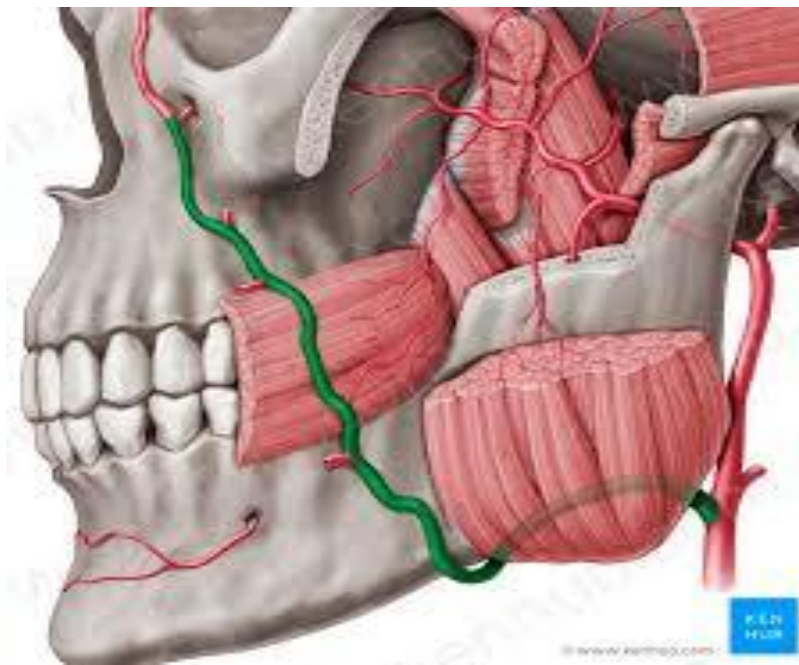
Orbicularis oculi



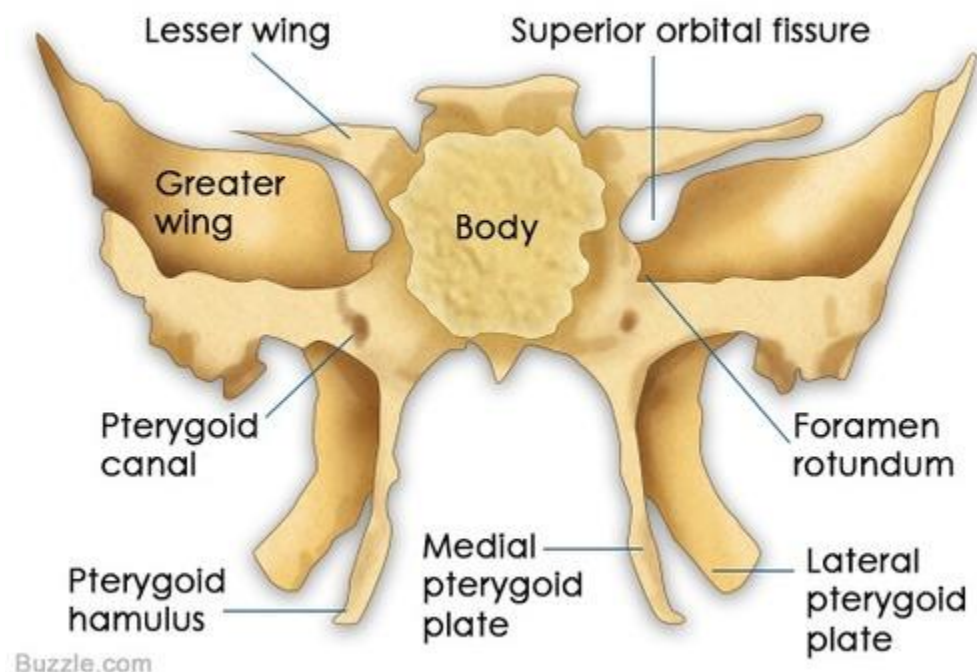
Orbicularis oris



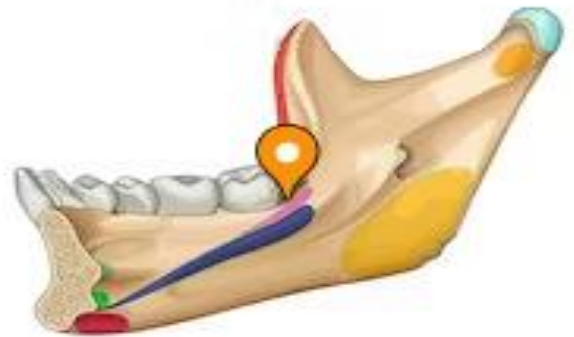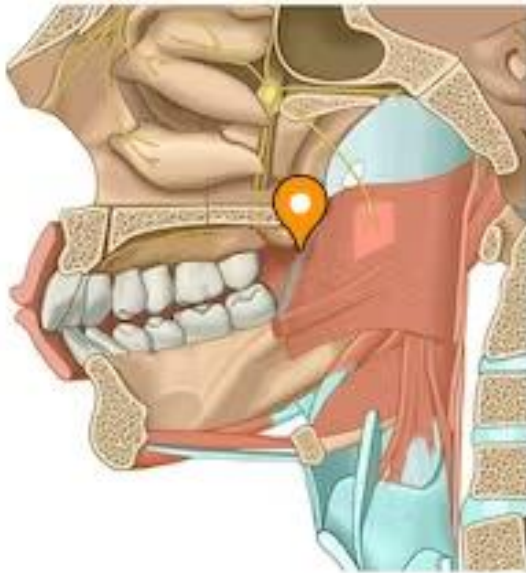Buccinator



POSTERIOR VIEW

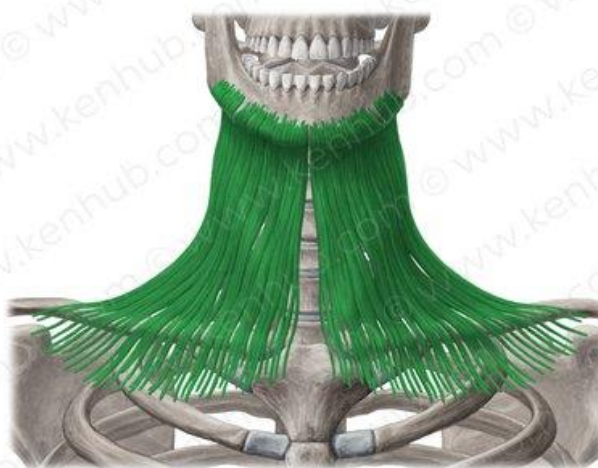

Attachment of petrygomandibular ligament to mylohyoid line of the mandible

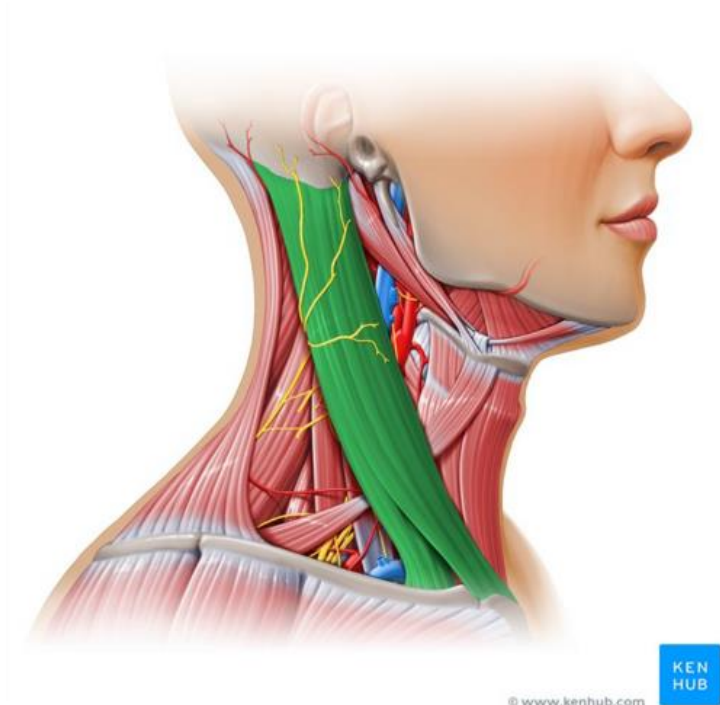


Petrygomandibular ligament

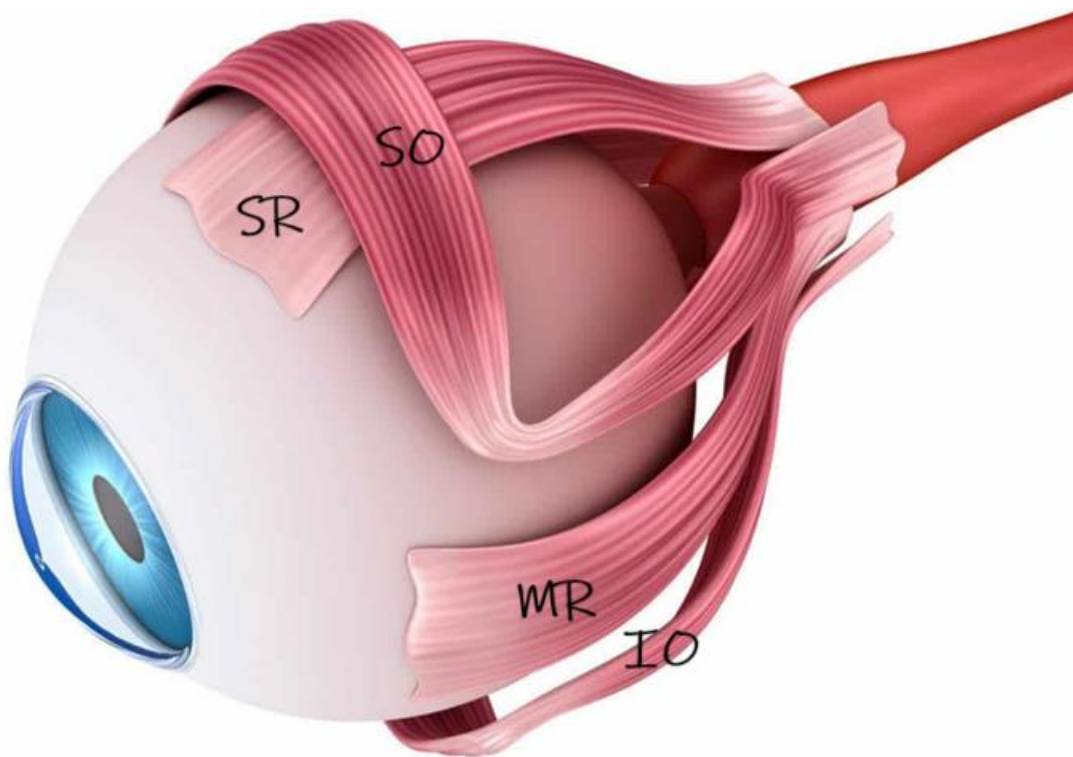
Platysma muscle

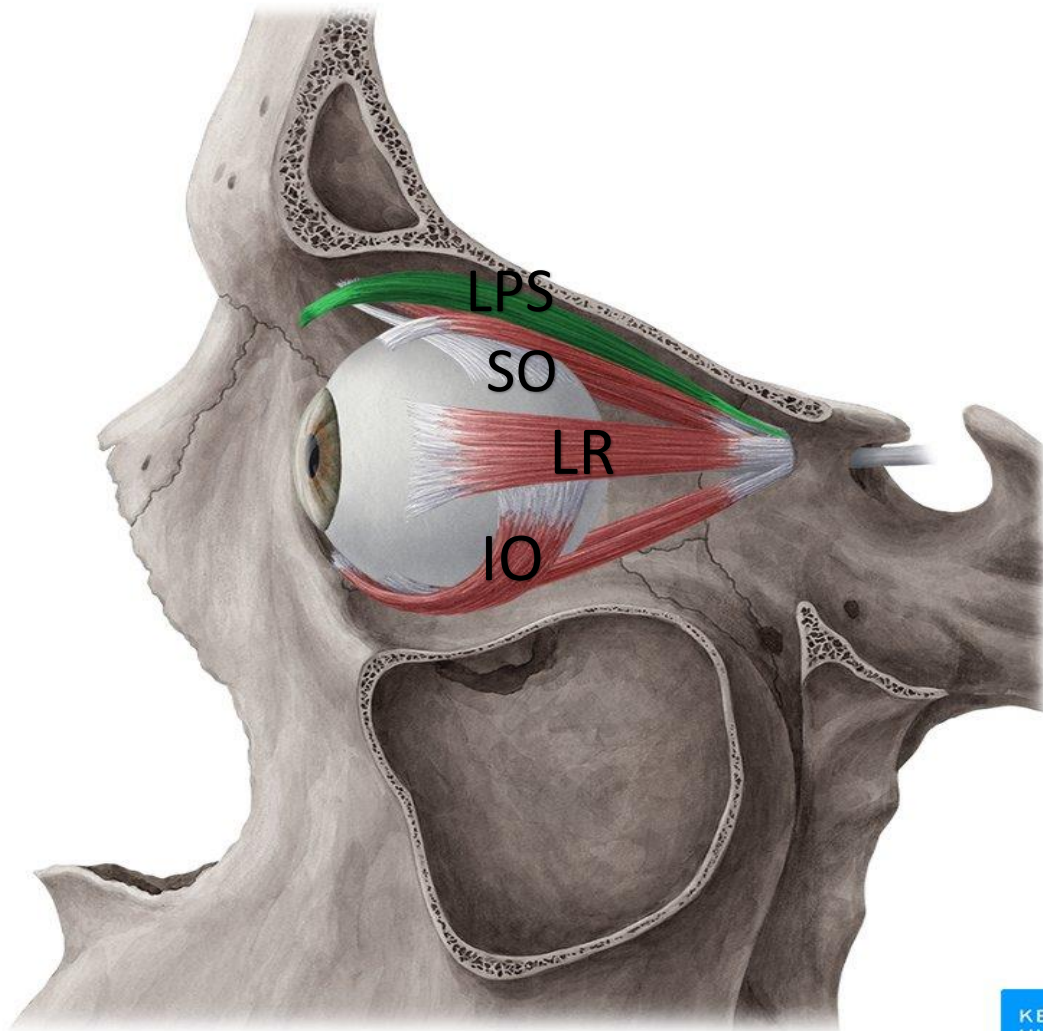


sternomastoid Muscle

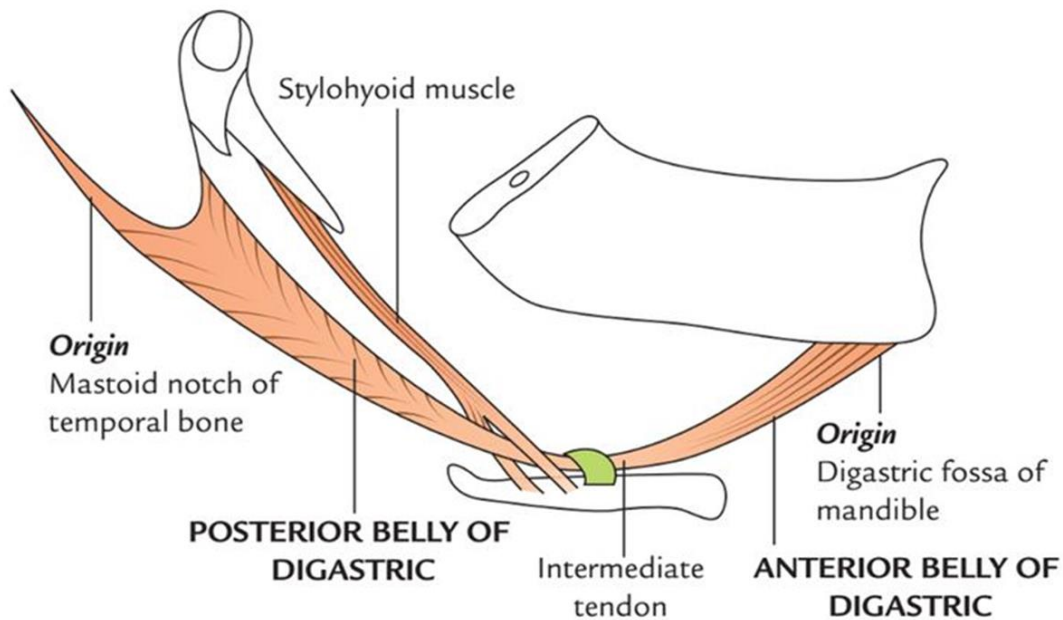


Extra- ocular muscles

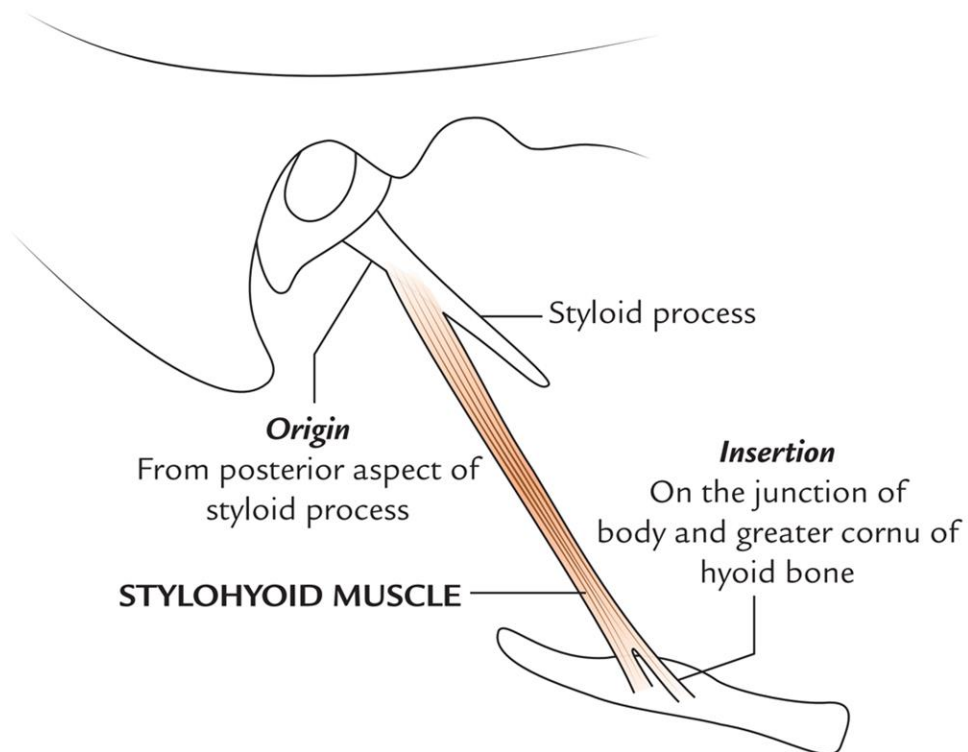




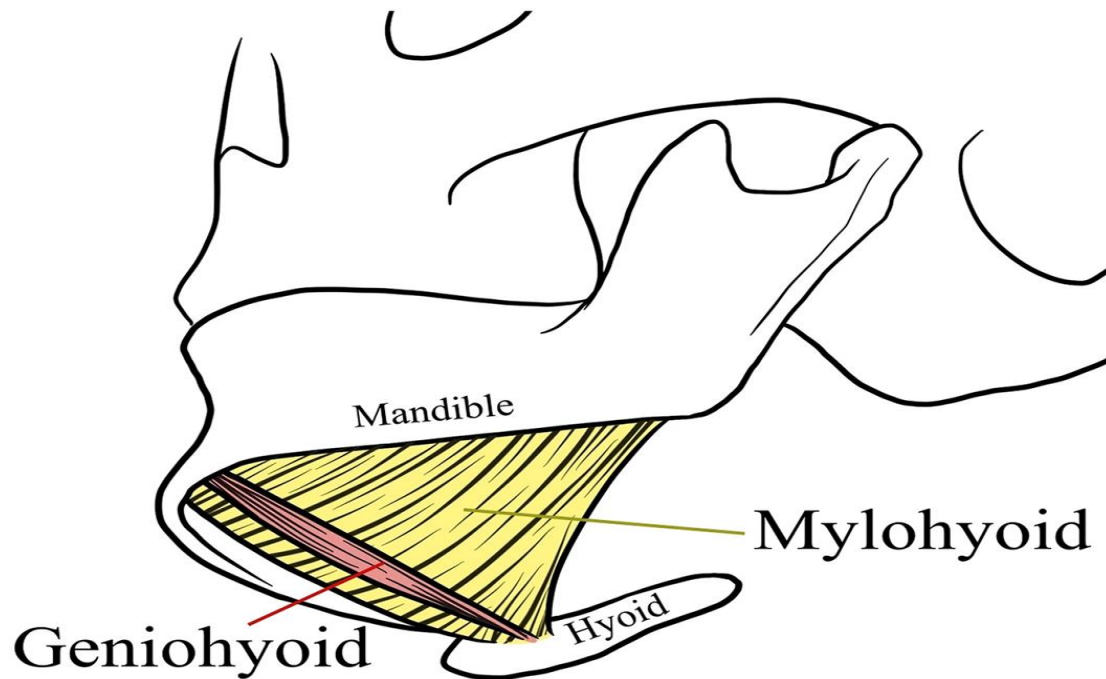
Digastric muscle



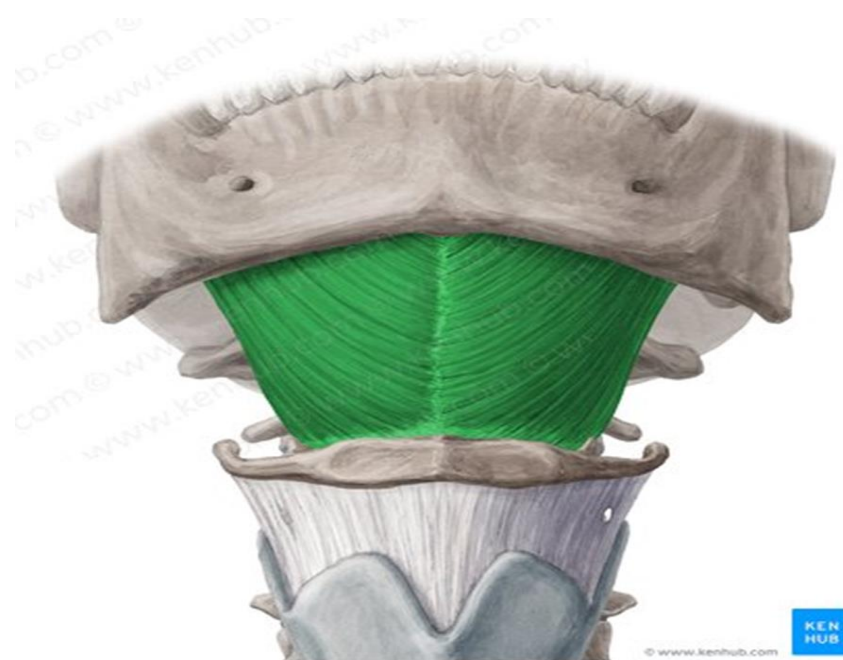
Stylohyoid muscle



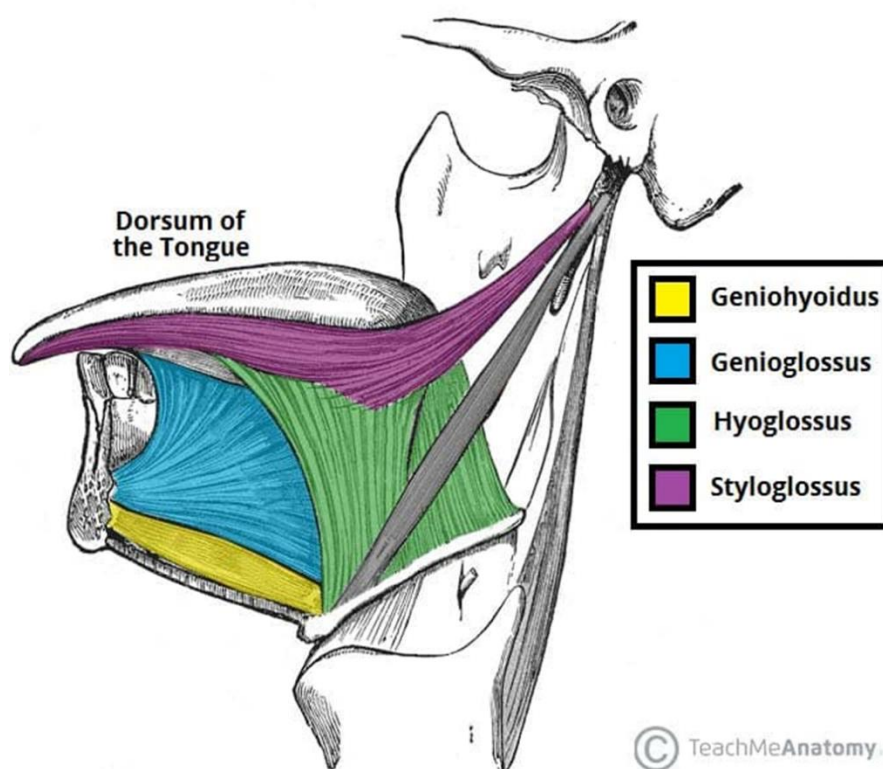
Geniohyoid muscle



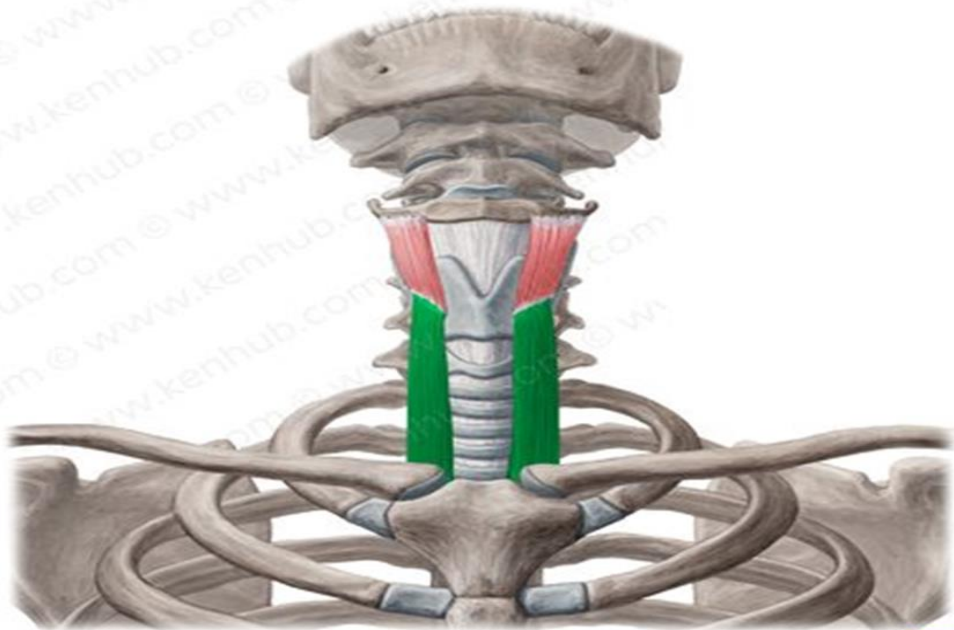
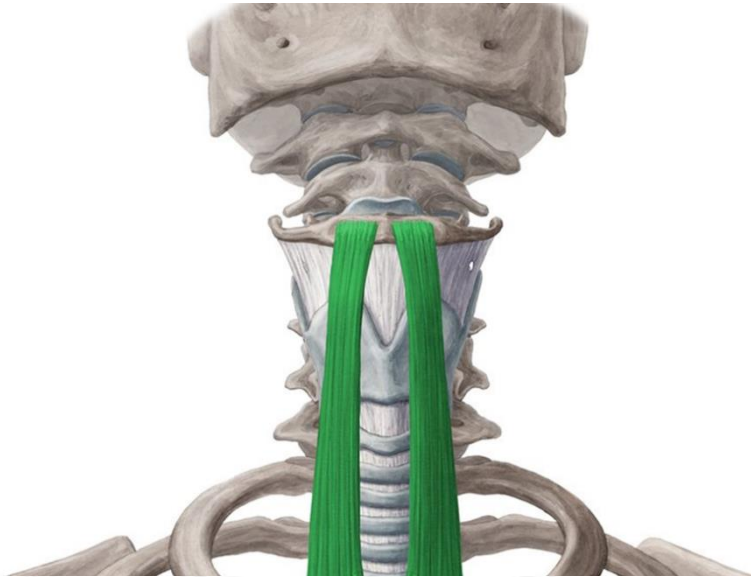Mylohyoid muscle



Hyoglossus muscle



Sternohyoid muscle

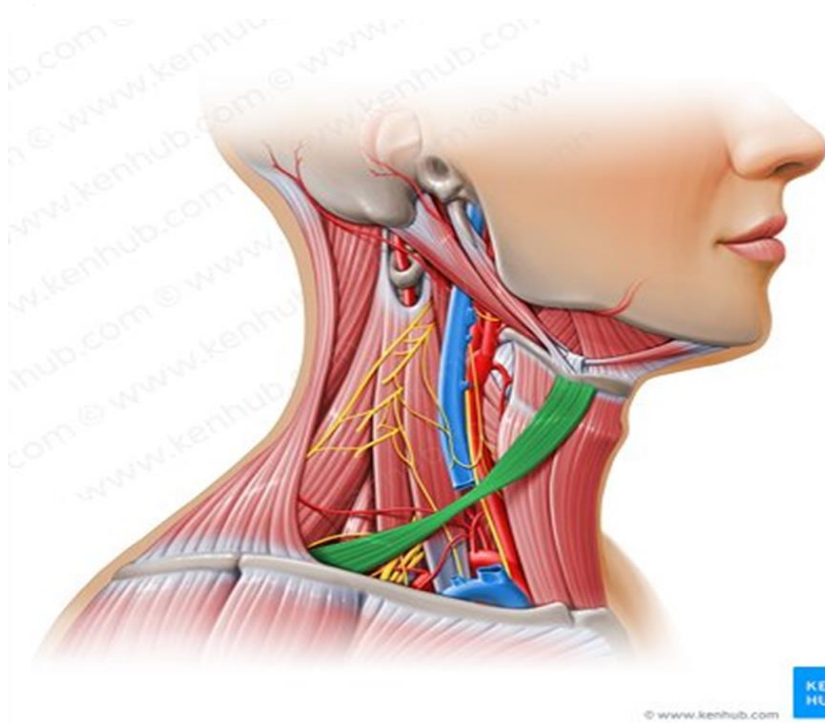
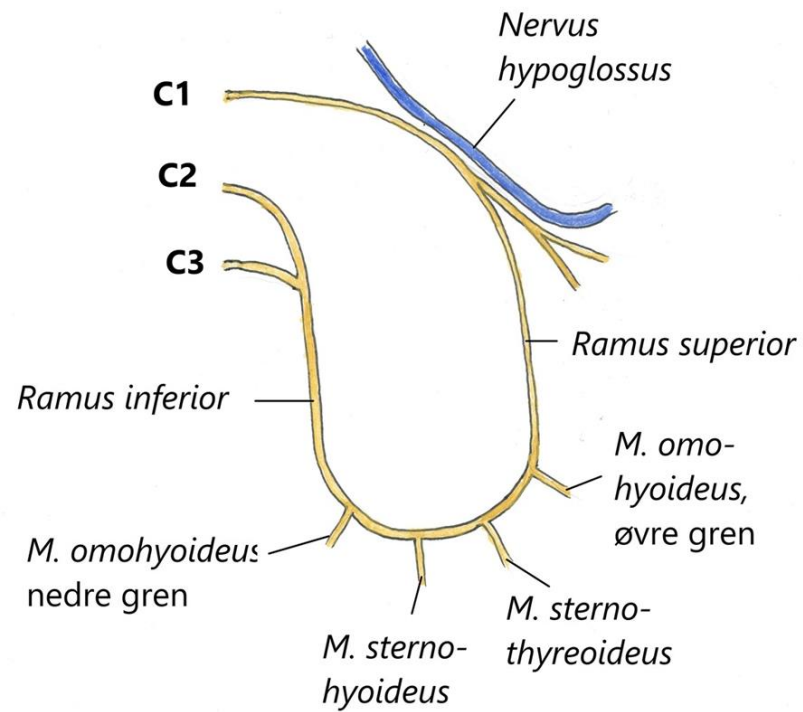


© www.kenhub.com



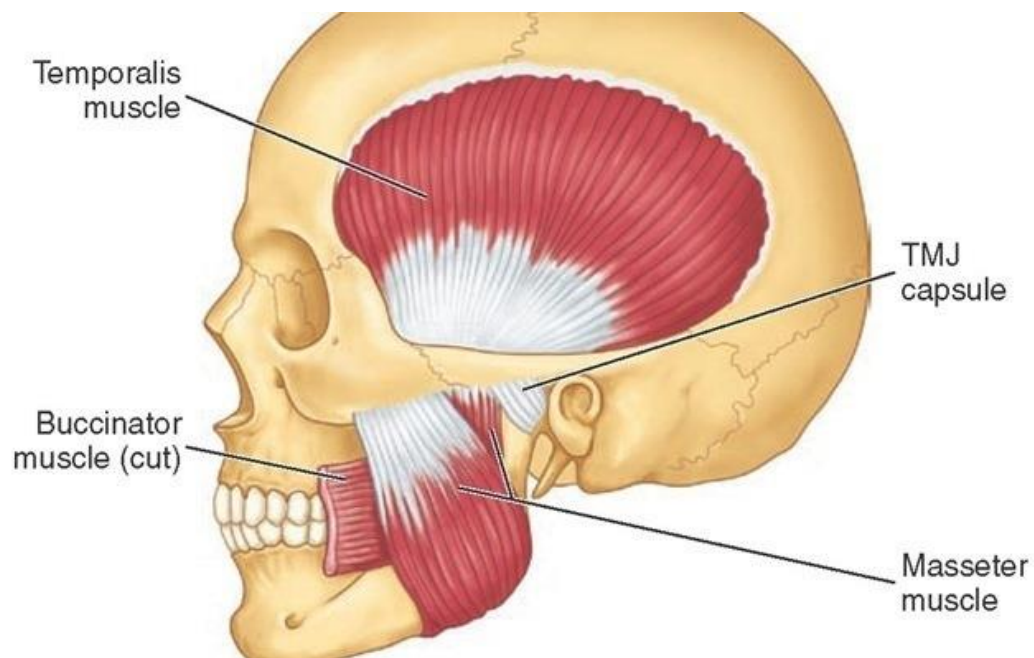
Sternothyroid & Thyrohyoid Muscles

Ansa cervicalis

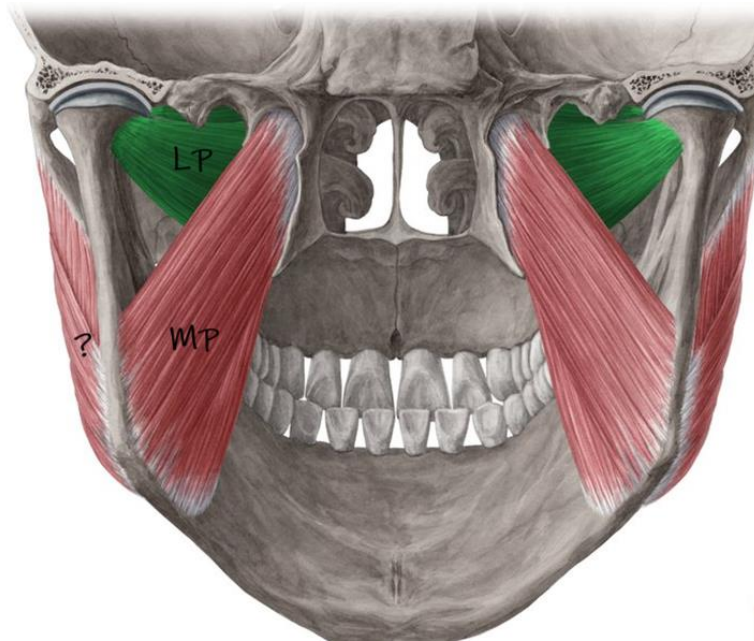


Omohyoid muscle

Temporalis and masseter



Medial & lateral pterygoid muscles



Goodbye & Good Luck

