

CARDIOVASCULAR SYSTEM EXAMINATION

H: Hello “Introduce yourself , take permission & Confirm patient identity”

E: Explain What are going to do & Exposure “ above the waist”

L: Light

P: Privacy “ ask for chaperone” & Position “ At 45 degree”

GENERAL examination

Hands: Periperal cyanosis , Capillary refill , Splinter hemorrhage , Clubbing , Tar staining, Osler node , Janeway lesion , Temperature , then take PR (Check for Radio-Radial delay and Radio-Femoral delay) , RR , tremor & measure BP.

Eyes: Xanthelasma , Corneal arcus , Conjunctival pallor and petechial hemorrhage.

Face: tounge for central cyanosis, Malar flush .

Neck: JVP

Lower Limbs : Ankle edema

PRECORDIUM Examination

Inspection(from 2 Sites)

From the **foot** of the bed & from **Right** Side of the patient

- 1- Symmetry of the chest
- 2- Chest deformities
- 3- Attached devices & drains
- 4- Breathing pattern

- 1- Visible Scars (Sternotomy)
- 2- Superficial masses or swelling
- 3- Visible Pulsation

Palpation (Is There Any Pain ?)

- 1- Heart : Apex beat (lt. Sided heaves) & Rt. Sided (left parasternal) heave.
- 2- Thrill : The tactile equivalent of a murmur (Palpable vibration).

Auscultation:

- 1- Heart Sound Vs. Added Sound
- 2- Murmur on ALL areas Of 4 Valves with bell and diaphragm
 - Auscultate carotid & axilla for radiation.
 - With 2 maneuvers for AR & MS
 - Don't forget to Auscultate Lung bases.

Thank the patient and clean your hands

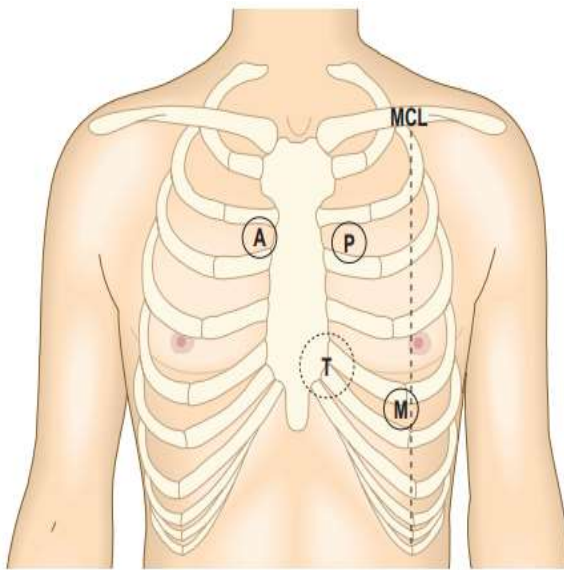
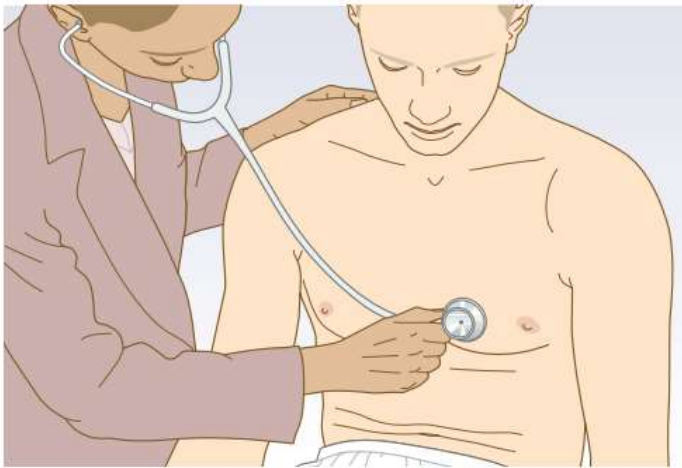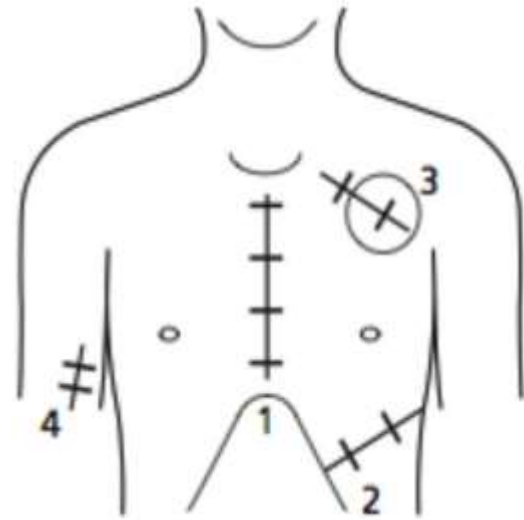
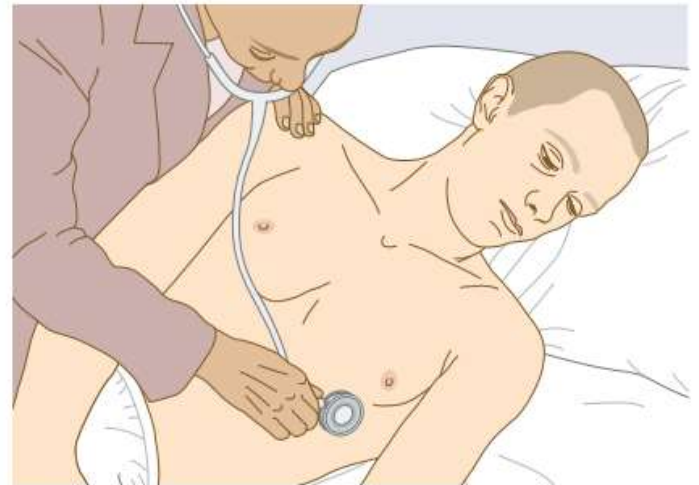


Fig. 4.17 Sites for auscultation. Sites at which murmurs from the relevant valves are usually, but not preferentially, heard. A, aortic; M, mitral; MCL, mid-clavicular line; P, pulmonary; T, tricuspid.



B

For Aortic Regurgitation



A

For Mitral Stenosis

RESPIRATORY SYSTEM EXAMINATION

H: Hello “Introduce yourself , take permission & Confirm patient identity”

E: Explain What are going to do & Exposure “ above the waist”

L: Light

P: Privacy “ ask for chaperone” & Position “ At 45 degree”

Inspection(from 2 Sites)

From the **foot** of the bed & from **Right** Side of the patient

- 1- Symmetry of the chest
- 2- Chest deformities
- 3- Accessory muscle use
- 4- Attached devices & drains
- 5- Breathing pattern

- 1- Visible Scars (Thoracotomy)
- 2- Superficial masses or swelling
- 3- Dilated veins
- 4- You Should inspect **Axilla**

General examination

Hands: Clubbing , Tar staining , Muscle wasting then take PR RR, tremor.

Eyes: Ptosis , Miosis , Conjunctival pallor .

Face: Plethoric face , tongue for central cyanosis.

Neck: JVP , Lymphnodes & Trachea.

Lower Limbs : Ankle edema

Chest Examination

Inspection (from 2 Sites) AS ABOVE

Palpation (Is There Any Pain ?)

- 1- Trachea : For tracheal deviation + Cricosternal distance
- 2- Heart : Apex beat & Rt. Sided (left parasternal) heave.
- 3- Chest expansion .
- 4- Tactile Vocal fremitus.

Percussion (Compare right with left, from **TOP** to bottom, then axilla).

Auscultation (Deep breaths; compare right with left, from top with bottom, then axillae) :

- 1-Breathing Sound Vs. Added Sound
- 2-Vocal resonance.

Thank the patient and clean your hands

Common causes of tracheal deviation		
Away from the side of the lesion	Towards to the side of the lesion	Upper mediastinal mass
Tension pneumothorax	Upper lobe consolidation	Retrosternal Goiter
Massive pleural effusion	Upper lobe fibrosis	Lung cancer
	Pneumoectomy	Lymphoma

Tactile vocal fremitus / Vocal Resonance	
Increased	Decreased
<ul style="list-style-type: none"> -Consolidation -Dense pulmonary fibrosis - Lobar collapse with patent major bronchi - Lung mass 	<ul style="list-style-type: none"> - Pleural effusion/ Haemothorax - Obesity - Pneumothorax - Collapsed lung with obstructed major bronchi

Percussion notes

Resonant	Hyperresonant	Dull	Stony dull
<ul style="list-style-type: none"> • Normal lung 	<ul style="list-style-type: none"> • Pneumothorax 	<ul style="list-style-type: none"> • Pulmonary consolidation • Pulmonary collapse • Severe pulmonary fibrosis 	<ul style="list-style-type: none"> • Pleural effusion • Haemothorax

ABDOMINAL EXAMINATION

H: Hello “Introduce yourself , take permission & Confirm patient identity”

E: Explain What are going to do & **Exposure** “ xiphisternum to the symphysis pubis,”

L: Light

P: **Privacy** “ ask for chaperone” & **Position** “ SUPINE (lying flat) ”

GENERAL examination

Hands: Clubbing, Koilonychia (spoon-shaped nails) and signs of chronic liver disease, including leuconychia (white nails), Flapping Tremor , Dupuytren’s Contracture and palmar erythema .

Eyes: Conjunctival pallor , Scleral Jaundice and Red eye .

Face: Mouth for IDA (angular cheilitis , atrophic glossitis) ,B12 Def. (beefy raw tongue) and Aphthous ulcer , Parotid enlargement .

Neck: for lymph nodes (Scalene LNs).

Chest : Gynecomastia , Hair Distribution & Spider Naevi.

Abdominal Examination

Inspection(from 2 Sites)

From the **foot** of the bed & from **Right** Side of the patient

- 1- Symmetry of the Abdomen
- 2- Umbilicus (central & inverted)
- 3- Abdominal Respiration
- 4- Attached devices & drains

- 1- Visible Scars
- 2- Superficial masses or swelling
- 3- Visible Dilated veins
- 4- Skin bruising

Palpation (Is There Any Pain ? If so; leave that area to the last.)

- 1- **Superficial Palpation :** a.Gain patient’s confidence. b.Superficial Masses & Superficial Tenderness.
- 2- **Deep Palpation :** a.Deep Masses. b.Deep Tenderness.
- 3- **Palpation For Organomegaly:** - Liver, Spleen & Kidneys.
 - A. hepatomegaly: start from RIF move your hand **vertically** with each inspiration.
Liver SPAN by Percussion starting from Right 5th intercostal space till **dullness appears**.
 - B. Splenomegaly: start from RIF move your hand **obliquely** with each inspiration.
 - C. Kidney : Ballotement test & Renal angle tenderness .

Percussion (Percuss all over 9 regions)

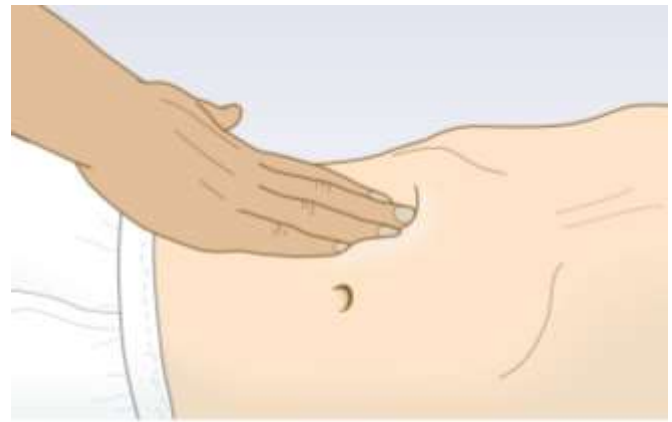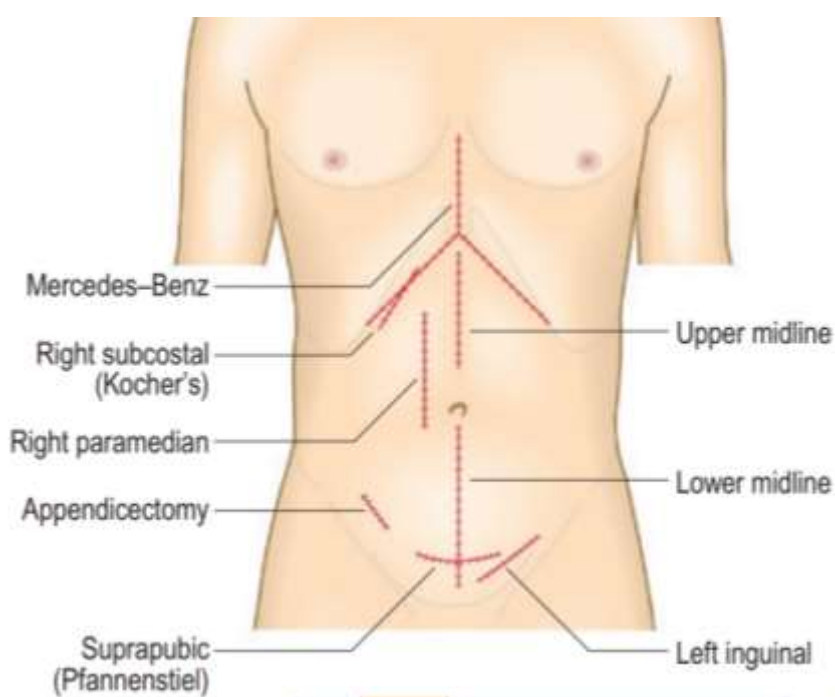
- Normally it should be **tympanic**
- Over mass or fluid (**dull**)
- Percuss for Ascites (**Shifting dullness** “mild to moderate” & **Transmitted Thrills**).

Auscultation:

- Auscultate for bowel sounds “ at ileocecal valve” & for bruit over renal & iliac arteries.

Mention that you have to do DRE & hernial orifices exam.

Thank the patient and Clean your hands



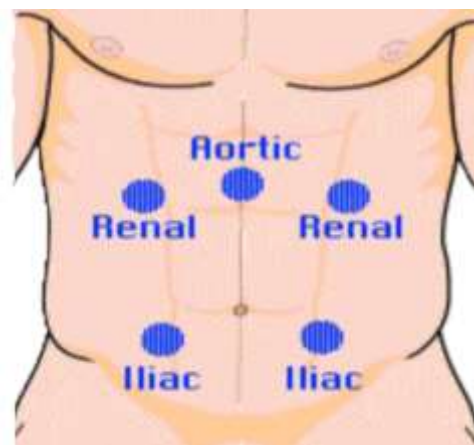
Palpation of the liver.

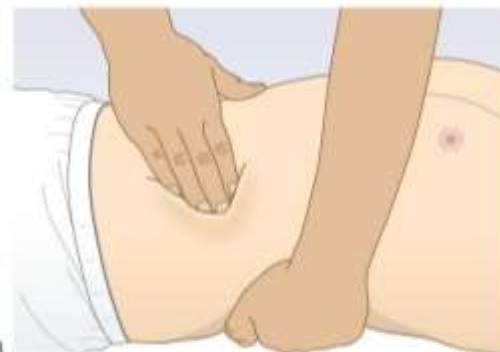
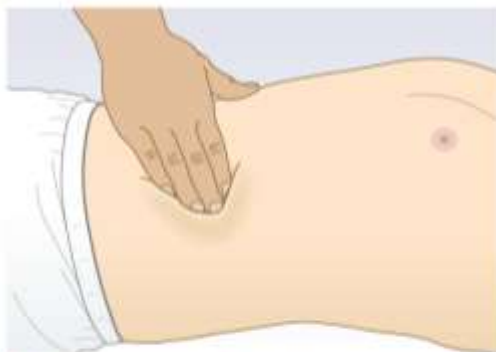
Fig. 6.16 Palpation of the spleen. **A** Initial palpation for the splenic edge moving diagonally from the umbilicus to the left hypochondrium. **B** If the spleen is impalpable by the method shown in A, use your left hand to pull the ribcage forward and elevate the spleen, making it more likely to be palpable by your right hand.

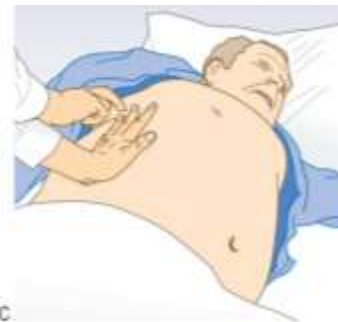
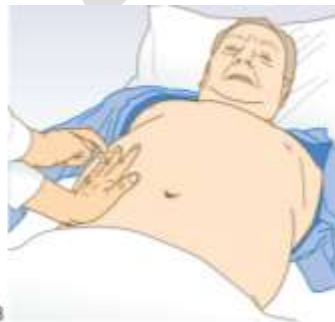
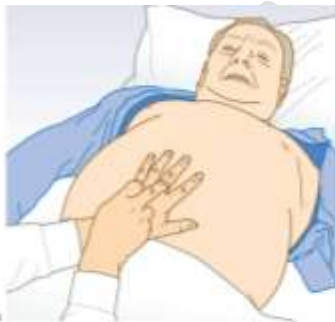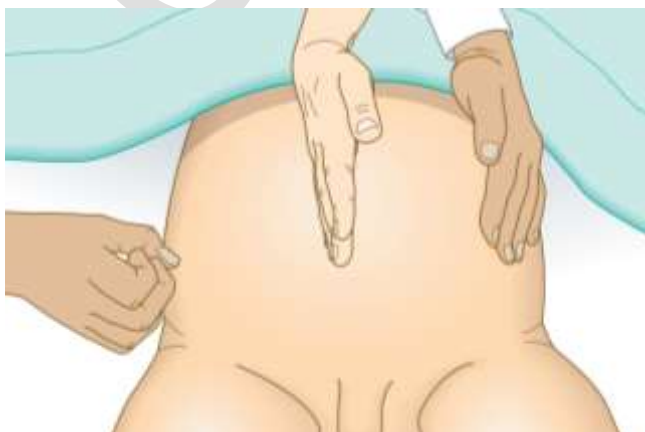Fig. 6.17 Percussing for ascites. **A** and **B** Percuss towards the flank from resonant to dull. **C** Then ask the patient to roll on to their other side. In ascites the note then becomes resonant.



THYROID EXAMINATION

H: Hello “Introduce yourself , take permission & Confirm patient identity”

E: Explain What are going to do & **Exposure** “ (NIPPLES & Above)”

L: Light

P: Privacy “ ask for chaperone” & **Position** “ Sitting ”

GENERAL examination

Hands: thyroid acropachy , Sweaty hand , fine Tremor , palmar erythema and pulse .

Eyes: exophthalmos , lid retraction, lid lag and Ophthalmoplegia (eye movement).

Face: dry coarse hair, periorbital puffiness or loss of lateral 1/3 of eyebrows .

Lower limb: pretibial myxedema.

Neck Examination

Inspection

From the **front** with the patient slightly extending his neck.

- 1- Symmetry
- 2- Swelling
- 3- Scars
- 4- Ask the patient to **swallow** and to **protrude his tongue**

Palpation (Is There Any Pain ?)

Palpation from Front

- Tracheal deviation
- Tenderness
- Any masses

Palpation from behind

- Palpate the 2 lobes of the thyroid
- Ask the patient to swallow while palpation
- Cervical and supraclavicular LNs

Percussion (Percuss over the sternum if dull → Retrosternal goiter)

Auscultation

Over the neck for thyroid bruit

Thank the patient and clean your hands

LOWER LIMB EXAMINATION

H: Hello “Introduce yourself , take permission & Confirm patient identity”

E: Explain What are going to do & **Exposure** (from the groin and below but mid-thigh is accepted)

L: Light

P: Privacy “ ask for chaperone” & **Position** “ Supine , Lying flat ”

Inspection all From the foot

- 1- Attached devices & drains
- 2- Symmetry or Swelling
- 3- Deformities & **Amputation**

- 1- Hair & Nails
- 2- Redness (change in color).
- 3- Skin lesions (**ULCERS**, scars).
- 4- Dilated or Guttering of veins.
- 5- Muscle wasting

- **Elevate** the leg looking for pressure ulcers or hidden abnormality.
- Examine **between toes**.

Palpation (Is There Any Pain ?)

- 1- **Tenderness, Temperature.**
- 2- **Capillary Refill .**
- 3- **Pulses:** (Dorsalis pedis, Posterior tibial, Popliteal, Femoral arteries & **R-F Delay**)
- 4- **Pitting edema**
- 5- **Inguinal LN Palpation “JUST Mention”**

Leg Circumference (both legs)

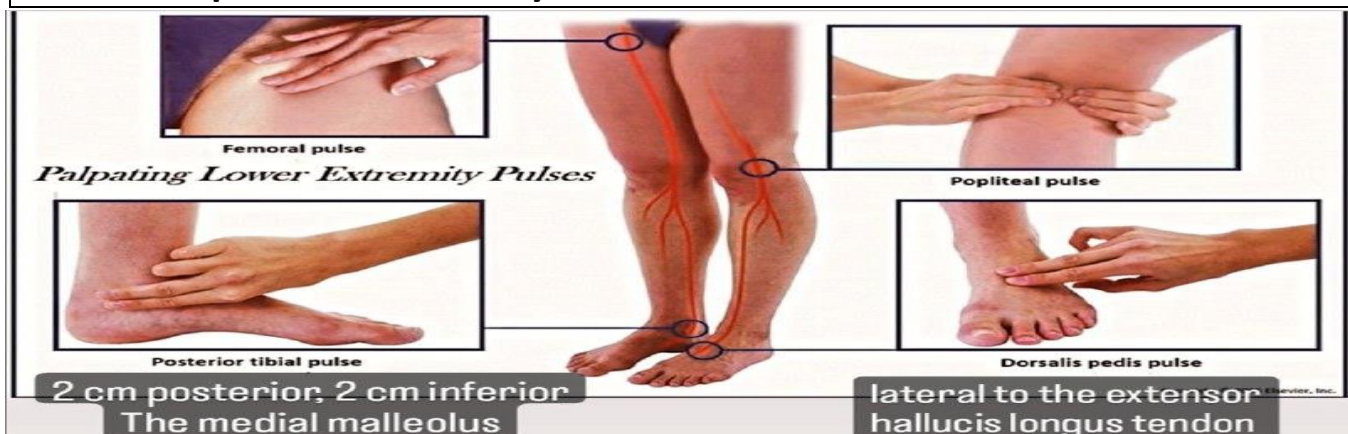
- Identify **anatomical landmarks** (Tibial tuberosity & medial malleolus)
- Attempt actual measurement .

Mention that you should do **Burger test & **ABPI** .**

Auscultation

Using the bell over the major arteries

Thank the patient and clean your hands



ULCER EXAMINATION

H: Hello “Introduce yourself , take permission & Confirm patient identity”

E: Explain What are going to do & **Exposure** “ (from the groin and below but mid-thigh is accepted)”

L: Light

P: Privacy “ ask for chaperone” & **Position** “ **Supine , Lying flat** ”

Inspection all From the **foot**

1- Site :

Medial aspect → venous , **Lateral** → Arterial , **At pressure site** → Neuropathic ulcer

2- Size

3- Shape

4- Edge

Sloping
(a healing ulcer)

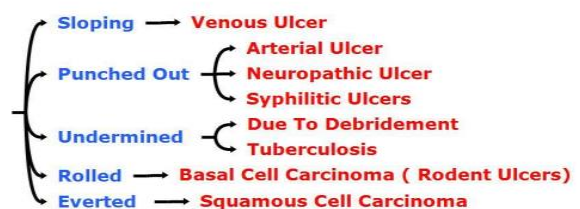
Punched-out
(syphilis, trophic)

Undermined
(tuberculosis)

Rolled
(basal cell carcinoma)

Everted
(squamous cell carcinoma)

FIG 1.15 The varieties of ulcer edge.



5- Floor “ **what you can see** ” :

→ Necrotic “Gray , Black ”

→ Pink , Granulation .

6- Discharge

7- Surrounding Skin → a. Swelling & Dilated veins b. loss of hair

Palpation (Is There Any Pain ?)

1- **Temperature** & **Tenderness** of Surrounding Skin

2- Palpate over the edge of ulcer

Soft → Healing Ulcer , **Firm** → Non-Healing Ulcer , **Hard** → Malignant

3- Feel the **base** “ **What you can feel when you palpate the floor** ”

Thank the patient and clean your hands

